

Cutaneous leishmaniasis: Report of rare cases in Nepal

S Neupane,¹ P Sharma,² A Kumar,¹ U Paudel¹ and DB Pokhrel¹

¹Department of Dermatology and Venereology, ²Department of Radiology and Imaging, Tribhuvan University Teaching hospital, Kathmandu, Nepal.

Corresponding author: Dr. Saraswoti Neupane, Department of Dermatology and Venereology, Tribhuvan University Teaching Hospital, Kathmandu, Nepal.

ABSTRACT

Cutaneous leishmaniasis is rare in Nepal although visceral leishmaniasis (kala azar) is common in the Terai region. In country like ours where tuberculosis is more prevalent cutaneous leishmaniasis is very likely to be mistreated as cutaneous tuberculosis, especially lupus vulgaris. Here we report a series of four cases of cutaneous leishmaniasis who presented in the out patient department at TUTH in the year 2006.

Keywords: Leishmaniasis, sodium stibogluconate, LD bodies.

INTRODUCTION

Leishmaniasis are a group of diseases caused by several species of the genus *Leishmania*. It has been estimated that 1.5 million new cases of cutaneous leishmaniasis occur annually and more than 80.0% of the total cases affect individuals in developing countries. Brazil, Iran, Afghanistan and Sudan suffer the highest prevalence and the disease is a priority for public health in all hyper endemic regions of the world.¹ Human leishmaniasis is usually classified as cutaneous and visceral or old world type and new world type.¹ The species involved in old world type are *L. major*, *L. tropica*, *L. aethiopica* and *L. donovani infantum*. The species responsible for new world type of cutaneous leishmaniasis are *L. mexicana*, *L. brasiliensis*.¹ It is transmitted by the bite of female sandfly of the genera *Phlebotomus* in Old world, *Lutzomyia* and *Psychodopygus* in the new world. Almost all of the cutaneous leishmaniasis pass through common stages of papule and nodule formation, central crusting, ulceration and healing with scar formation. In many instances a simple test like demonstration of Amastigotes in Giemsa-stained smears from infected skin by direct microscopy can easily confirm the diagnosis. Both systemic as well as local treatments are helpful.

In Nepal although kala azar is common in the Terai region, case of cutaneous leishmaniasis was not documented. Only recently first case of cutaneous leishmaniasis has been reported from Nepal.² Here we report a series of four cases of cutaneous leishmaniasis, in the year 2006, who were successfully treated with intralesional injection of sodium stibogluconate.

CASE 1

A 27 years old civil engineer from Syangja presented with non healing wound over right side of his face for 7 months. Patient had recently returned from Bosnia few months back, where he had worked as an engineer. Initially the lesions started as two acne like painless

eruptions over right side of his face. The lesions became pustular, which gradually broke up into an ulcer. There was no history of fever and pain. Patient had already received full course of anti tubercular treatment from elsewhere, but the lesion was gradually progressing despite the treatment.

Examination revealed erythematous plaque over right infra auricular region measuring 4x3 cm with surface ulceration and crusting. The plaque was non-tender and

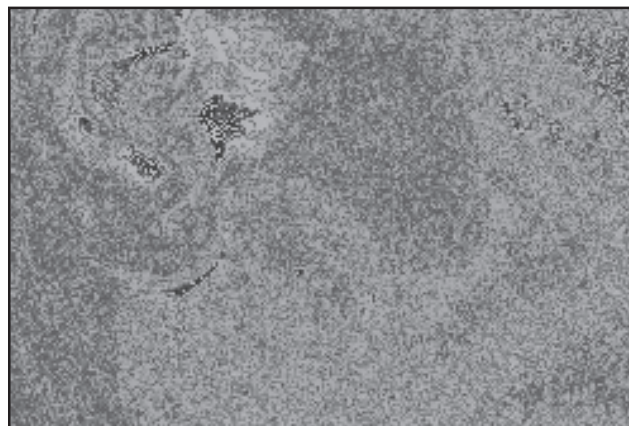


Fig. 1. Erythematous plaques with surface ulceration and crustations

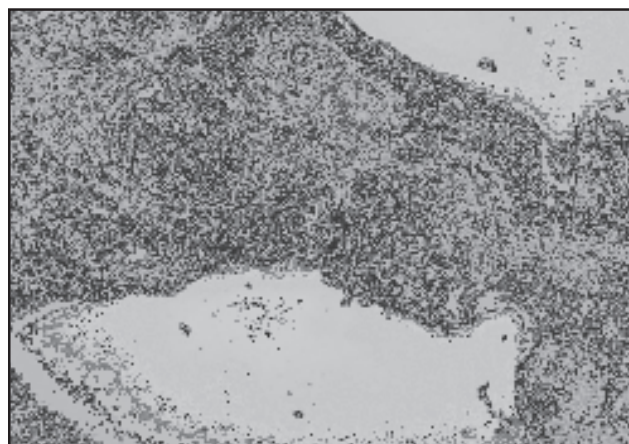


Fig. 2. Keratinized stratified squamous epithelium with presence of numerous round to oval structure of small size (LD bodies) intracellularly and extracellularly in the dermis




Fig. 3. Healed lesions with post inflammatory hyperpigmentation and scarring

non-indurated. Similar plaque measuring 3x2cm was present over the right zygomatic region (Fig. 1).

Investigations revealed Haemoglobin of 14 gm % and ESR of 10 mm/hr. Mantoux test was negative and chest x- ray was normal. No growth was seen after six weeks of inoculation in tissue culture for mycobacteria. Similarly fungal culture was negative. Impression smear from base of ulcer showed squamous epithelial cells, inflammatory cells and macrophages. Small intracellular (within macrophages) and extra cellular parasites were also seen. Histopathological examination revealed LD bodies (Fig. 2).

Patient was treated with intralesional injection of sodium stibogluconate every alternate day. After 14 doses the lesions healed with post inflammatory hyperpigmentation.

CASE 2

A 33 years old engineer from Lalitpur presented with non-healing wound over the nose and dorsum of left wrist for 5 months. Initially it was a small papular eruption which gradually became nodular and then finally ulcerated and increased in size. There was no pain, itching, fever or weight loss. He did not give any significant travel history but he had visited the far western region of Nepal in the past.

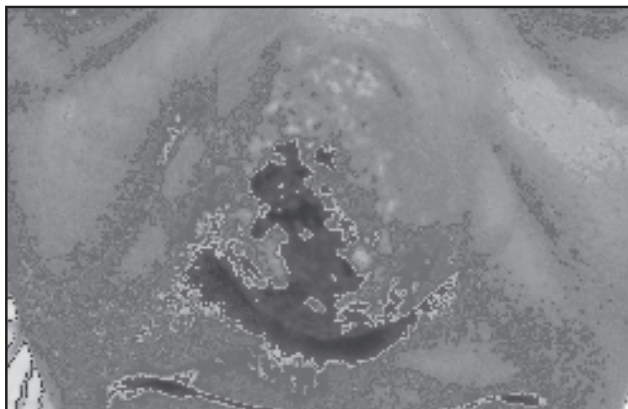


Fig. 4. Erythematous ulcerated plaque

Examination revealed erythematous, non-tender, ulcerated, jelly-like plaque of 4x3 cm on the nose with surrounding erythema upto the malar region (Fig. 4). Similar plaque of 1.5x1 cm was present over the dorsum of left wrist.

Investigations revealed total count of 7800 WBC/cu.mm with N – 52.0%, L – 46.0%. Haemoglobin was 17.9 gm %. ESR- 10 mm/hr, Mantoux test was negative. Skin smear for AFB was negative. Fungal elements were also not seen. K-39 was negative. Histopathology report showed epidermis with hyperkeratosis, parakeratosis, epithelial hyperplasia and focal surface ulceration. Dermis showed multiple confluent granulomas composed of histiocytes, epitheloid cells, lymphocytes and plasma cells. Cytoplasm of most of the histiocytes showed LD bodies. LD bodies were seen in Giemsa stain. Dermal nerves appeared normal. Acid fast stain for lepra bacilli was negative.

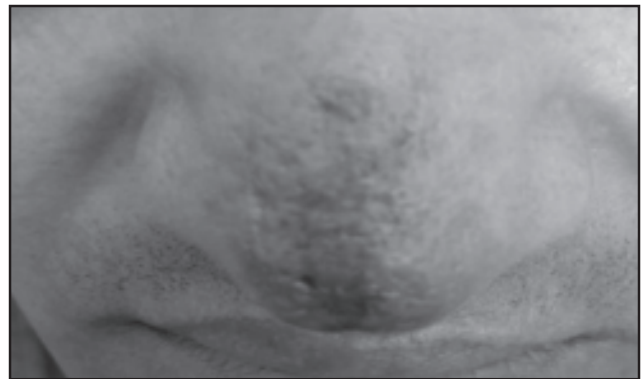

Fig. 5. Healed lesion over the nose with scarring

He was similarly treated with intralesional injection of Sodium stibogluconate, initially alternate day and later once weekly. Lesion over the wrist was secondarily infected so had to be treated with a course of oral and topical antibiotics. Both the lesions healed with 14 and 40 doses of intralesional injection respectively over the hand and face (Fig. 5).

CASE 3

A 40 years female from Bara district presented with painless non-healing wounds over right leg and calf for 3 months. Initially the lesions started as a small papule that gradually increased in size. All the four lesions

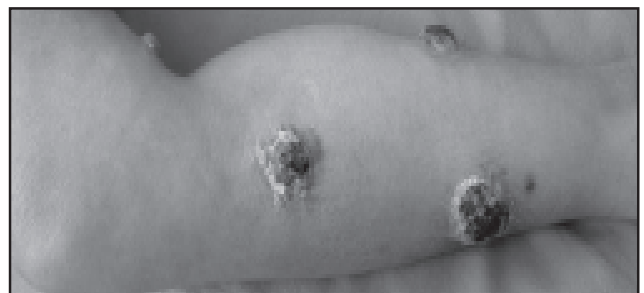

Fig. 6. Multiple Plaques with crustations over leg and popliteal fossa




Fig. 7. Lesion healed with scarring

started almost simultaneously over right leg and calf. There was no history of pain, itching, bleeding or trauma. Patient had returned from Saudi Arabia where she used to do the household works.

Local examination showed non tender, erythematous plaque with overlying thick crusts. They were 4 in number present over calf and anterior and posterior aspects of right leg. The lesions ranged from 2x3 to 3x4 cm (Fig. 6). Distal neurovascular status was normal.

Slit smear examination showed presence of macrophage laden with LD bodies. Extracellular LD bodies were also seen. Intralesional injection of sodium stibogluconate was given but the patient developed hypersensitivity to the drug after 14th dose and the lesions were still not improving. So, Carbon dioxide laser ablation was done. Finally the lesions healed with scarring after two sessions of CO₂ laser ablation (Fig. 7).

CASE 4

A 38 years old male from Chitwan attended with non-healing wound over the extensor aspect of right arm for 6 months. Initially the lesion had started with acne like eruption over the extensor aspect of right arm which then ulcerated and gradually increased in size. There was no pain, itching, bleeding or fever. The patient had

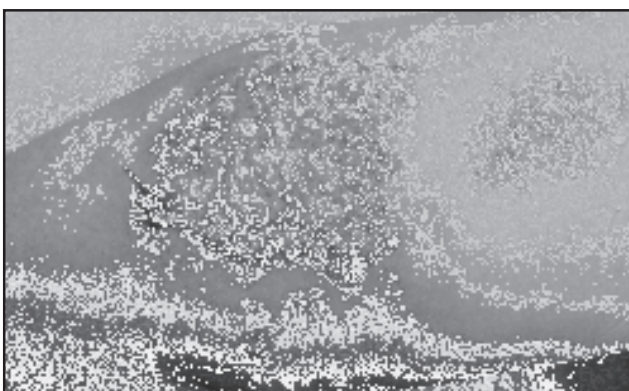


Fig. 8. Large plaque over right arm with satellite papules, nodules and sinuses

returned one month back from Sudan. Local examination revealed large erythematous plaque with superficial crustations measuring 6x5 cm, non tender over the extensor aspect of right arm. There were multiple satellite lesions surrounding the main plaque. The satellite lesions comprised of nodules, sinuses, abscesses and ulcerations with seropurulent discharge (Fig. 8). Haematological parameters were normal. X-ray right arm revealed no abnormal findings. Biopsy specimens showed LD bodies both intracellularly and extracellularly. Patient was treated similarly with intralesional injection of sodium stibogluconate (100mg/ml), initially every alternate day and once weekly later on. With 12 injections the lesion had healed with scarring.

DISCUSSION

Leishmaniasis is a major world health problem. The disease is endemic in 88 countries Brazil, Iran, Afghanistan and Sudan suffer the highest prevalence. It is caused by protozoa Leishmania. It may produce a variety of clinical syndromes varying from a simple ulcer to fatal systemic disease. Infection is transmitted by the bite of the sandfly, usually at night and outdoors. This fact is supported by our three engineer patients who had to work outdoors. It is imported into non - endemic countries by immigrants and returning travelers as in 3 of our patients. However, one of the patients did not give significant travel history outside Nepal. Incubation period: may range from few days to over a year.

All previously uninfected individuals are susceptible for cutaneous leishmaniasis. One or more lesions occur in unclothed parts of the body as in our cases. Clinical stages passes from papule, nodule, crusting, ulceration and finally healing with scarring. All of our cases presented with non healing ulcer which had started as papule subsequently progressed towards nodule formation, crusting and ulceration.

Diagnosis of cutaneous leishmaniasis can be confirmed by demonstration of amastigotes in Giemsa stained smears from infected skin by direct microscopy, intracellular amastigotes in the dermis of H & E (Haematoxylin and Eosin) stained sections from biopsy specimen, presence of leishmanial granulomas in the dermis in H and E specimens, growth of promastigotes in Nicolle-Novy-macNeal (NNN) culture medium from lesional specimens and demonstration of Leishmanial DNA by PCR . The clinical diagnosis is not difficult with typical clinical features in the endemic region. However in non endemic countries like Nepal where Cutaneous Leishmaniasis is not common, it can easily be missed. Clinical patterns are poor indicators of species.³ The species are distinguished by isoenzyme pattern and DNA analysis.

Most sores heal spontaneously, but their duration cannot be predicted in an individual case. Various therapeutic modalities have been used for treating cutaneous leishmaniasis. Intralesional pentavalent antimonial injection is one of the effective therapeutic modalities. Topical methods of treatment can be tried for simple sores. Alternate day or weekly intralesional treatment of cutaneous leishmaniasis with sodium stibogluconate has been shown to be more effective than daily treatments.⁴ Uzun S *et al* (2004) have shown the efficacy of intralesional sodium stibogluconate to be 97.2% with a low relapse rate of 3.9% and no serious adverse side effects.⁵ However some studies have shown combination of cryotherapy with intralesional injections of sodium stibogluconate, much more effective than the use of intralesional sodium stibogluconate alone.⁶ Systemic treatment with pentavalent antimonials is indicated for problematic sores like involvement of mucosa or cartilage, sores on the lower leg or over a joint, sores where scarring would be disabling or disfiguring and sores that might be due to parasites of the *L. brasiliensis* group. *L. aethiopicus* is only sensitive to Pentamidine. Hence species characterization is also an important aspect of management. Nevertheless, in our cases we were not able to identify the species due to lack of facilities for DNA analysis. All our cases were managed successfully with intralesional injection of sodium stibogluconate, except for one case, which was treated successfully with carbon dioxide laser ablation.


Although cutaneous leishmaniasis is rare in Nepal we came across four cases in a year which we feel, is sufficient enough to make clinicians aware of the disease while treating ulcers of long duration.

REFERENCES

1. Vega-Lopez F, Hay RJ. Parasitic worms and Protozoa-Leishmaniasis. In Burns T, Breathnach S, Cox N, Griffiths C, editors Rook's Textbook of Dermatology (7th edition); Massachusetts; Blackwell Science 2004; 32: 35-46.
2. Pandey B D, Babu E, Thapa S, Thapa L B. First case of cutaneous leishmaniasis in Nepalese patient: *Nepal Med Coll J* 2006; 8: 213-4.
3. Jafari AK, Akhyani M, Valikhan M, Ghodsi S, Barikbin B, Toosi S. Bilateral cutaneous leishmaniasis of upper eyelids: A case report. *Dermatol Online J* 2006; 12: 20.
4. Tallab TM, Bahamdad KA, Mirdad S *et al*. Cutaneous leishmaniasis: schedules for intralesional treatment with sodium stibogluconate. *Int'l J Dermatol* 1996; 35: 594-7.
5. Uzun TS, Durdu M, Culha G, Allahverdiyev AM, Memisoglu HR. Clinical features, epidemiology, and efficacy and safety of intralesional antimony treatment of cutaneous leishmaniasis: recent experience in Turkey. *J Parasitol* 2004; 90: 853-9.
6. Asilian A, Sadeghinia A, Faghihi G, Momeni A, Amini HA. The efficacy of treatment with intralesional meglumine antimoniate alone, compared with that of cryotherapy combined with the meglumine antimoniate or intralesional sodium stibogluconate, in the treatment of cutaneous leishmaniasis. *Ann Trop Med Parasitol* 2003; 97: 493-8.

FRUCTODEX[®]


Saline / Water



Efficient & Dependable

Jeevan Sanjeevani

- Provides 200 kcal/bottle
- Rapid utilization of carbohydrates
- Higher protein sparing effect
- Prevents fluid overload



RAPTAKOS, BRETT & CO. LTD.

Eidikos Division

253, Dr. Annie Besant Road,
Worli Colony Post office, Mumbai 400 030.
www.raptakos.com