

## Superior mesenteric artery syndrome: case report

*RC Shukla and R Pathak*

Department of Radiodiagnosis and Imaging, BHU, Varanasi, India

**Corresponding author:** Dr. Roshani Pathak, Department of radiodiagnosis and Imaging, BHU, India  
e-mail: drroshanipathak@yahoo.co.in

### ABSTRACT

Superior mesenteric artery (SMA) syndrome is a rare acquired disorder in which acute angulation of SMA causes compression of the third part of the duodenum between the SMA and the aorta, leading to obstruction. Loss of fatty tissue as a result of a variety of debilitating conditions is believed to be the etiologic factor causing the acute angulation. We report a case of 30 years old lady who presented with postprandial abdominal pain at the epigastric region, colic type without radiation accompanied by nausea, postprandial vomiting and weight loss. Esophageal gastric series revealed an abrupt interruption in the contrast medium flow at the level of the junction of third portion (midpart) of the duodenum in barium studies. A diverticula is noted just proximal to the site of obstruction. High resolution ultrasound and color Doppler sonography showed narrowing of the aortomesenteric angle to 22°. Duodenojejunostomy was performed in the patient. Unfortunately the patient later was admitted in the hospital for refractory gastroparesis associated with superior mesenteric artery syndrome. Although open and laparoscopic duodenojejunostomy have been described as the best surgical treatment options for Wilkie's syndrome, but further attention is needed to the management of patients with refractory symptoms of gastroparesis after corrective surgery.

**Keywords:** Superior mesenteric artery syndrome, Wilkie's syndrome, arteriomesenteric duodenal compression.

### INTRODUCTION

Superior mesenteric artery (SMA) syndrome is a rare cause of upper gastrointestinal obstruction.<sup>1</sup> It was first described by Von Rokitansky in 1842 and popularised later by Wilkie. It is also known as SMA syndrome, cast syndrome and arteriomesenteric duodenal compression.<sup>2</sup> SMA syndrome is a rare entity in which the third part of duodenum is compressed by the SMA, causing acute or chronic duodenal obstruction. It is seen in patients with rapid weight loss, those in plaster body casts, hip spica casts, or in traumatic quadriplegias, in which there may be sudden loss of weight and patient may be positioned supine for prolonged periods.<sup>3</sup>

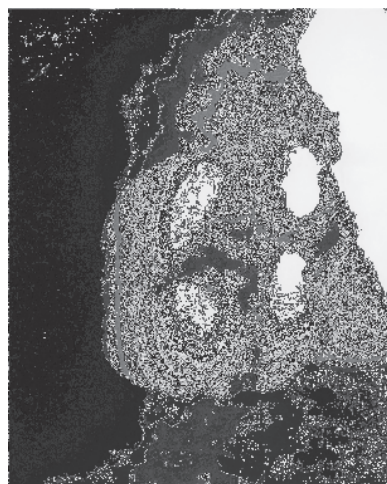
### CASE REPORT

A 30 years old lady, presented with postprandial abdominal pain at the epigastric region, colicky type without radiation, accompanied by nausea, postprandial vomiting and weight loss. She was treated in terms of tuberculosis before she came to this hospital. All blood tests including serum electrolytes and liver function tests were normal. Esophageal gastric series revealed an abrupt interruption in the contrast medium flow at the level of the junction of third portion (midpart) of the duodenum in barium studies (Fig 1). A diverticula is noted just proximal to the site of obstruction (Fig 1). High resolution ultrasound and color Doppler sonography showed narrowing of the aortomesenteric angle to 22° (Fig 2. a. and 2. b.). A diagnosis of Wilkie's

syndrome was made on the basis of clinical suspicion, upper GI barium studies, high resolution USG and color Doppler findings. Duodenojejunostomy was performed in the patient. Unfortunately the patient later was admitted in the hospital with the symptoms of refractory gastroparesis associated with superior mesenteric artery syndrome.

### DISCUSSION

Superior mesenteric artery syndrome is a rare condition. Only 400 cases have been reported so far.<sup>4</sup> The Superior



**Fig. 1.** An abrupt interruption in the contrast medium flow at the level of the junction of third portion (midpart) of the duodenum in barium studies along with a diverticulum just proximal to the site of obstructio

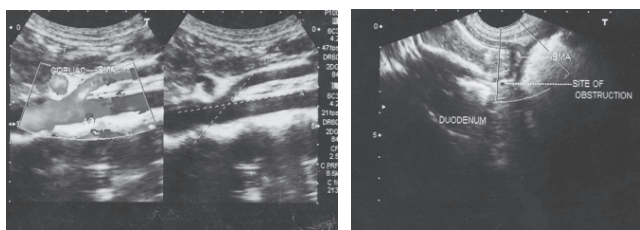


Fig. 2 a

Fig. 2 b

Color Doppler sonography showing narrowing of the aortomesenteric angle and site of obstruction respectively

Mesenteric Artery usually forms an angle of approx.  $45^{\circ}$  with the abdominal aorta at its origin, while the third part of the duodenum crosses in between the SMA anteriorly and aorta posteriorly. Any factor that sharply narrows this aortomesenteric angle (to less than  $25^{\circ}$  approx.) can cause entrapment and compression of the third part of the duodenum as it passes between the SMA and aorta, resulting in the Superior Mesenteric Artery Syndrome.<sup>5</sup>

It is characterized by features of acute or chronic upper gastro-intestinal tract obstruction, and, although the exact aetiology is not known, the syndrome has been associated with sudden weight loss, spinal surgery, cast application, and, rarely, abdominal aortic aneurysm and pan-creatitis<sup>6</sup>. Alternatively other causes implicated include high insertion of duodenum at the Ligament of Treitz, a low origin of SMA and compression of duodenum due to peritoneal adhesions.<sup>5</sup> It usually affects young females (10 to 39 years). The symptomatology is commonly chronic, with epigastric pain, bloating after meals, and vomitings. An acute presentation is uncommon.<sup>6</sup>

The most helpful roentgenologic sign is a line of obstruction in the third part of the duodenum passing obliquely towards the right lower quadrant corresponding to the course of the superior mesenteric vessels. The obstruction may be total in acute forms. In less complete obstruction, other changes have to be carefully looked for. The obstructions are usually not total and diagnosis is more difficult. The radiologist's role in these cases is to establish a diagnosis and help plan management by determining the value of positional changes, and to follow the role of conservative and operative management.<sup>7</sup>

Thus, the findings of SMA syndrome in upper GI study are very important. It reveals the characteristic dilatation of the first and second parts of the duodenum, with an abrupt vertical or linear cutoff in the third part with normal mucosal folds. Very little barium is seen to pass into jejunum during the early part of the examination. And, other finding includes delay of 4-6 hours in gastroduodenojejunal transit.<sup>8</sup> Unfortunately, these

radiologic appearances are nonspecific for the SMA syndrome and have been reported in various conditions such as scleroderma, diabetes, pancreatitis, peptic ulcer and malignant lymph nodes or tumors in the root of the mesentery in older patients.<sup>9</sup>

Conservative management is the rule for acute cases.<sup>4</sup> Conservative management, consisting of frequent and small feedings has been successful at times and should be tried initially; particularly in late cases.<sup>8</sup> Surgery is indicated for chronic cases and failure of conservative management. Duodenojejunostomy is the procedure of choice and is effective in 90% of patients.<sup>4</sup> Cleavage of the ligament of Treitz is another option, enabling the duodenum to drop away from the apex of the sharpened aorto-mesenteric angle.<sup>10</sup> Laparoscopic duodenojejunostomy for the management of SMA has also been described in the literature.<sup>8</sup>

Gastroparesis after correction surgery is a frequently encountered problem related to gastric and duodenal atony. Although the presence of such persistent symptoms has been described in the literature, there is little information on their management. Although open and laparoscopic duodenojejunostomy have been described as the best surgical treatment options for Wilkie's syndrome, but further attention is needed to the management of patients with refractory symptoms of gastroparesis after corrective surgery.<sup>2</sup>

#### REFERENCES

- Roy A, Gisel JJ, Roy V, Bouras EP. Superior Mesenteric Artery (Wilkie's) Syndrome as a Result of Cardiac Cachexia. *J Gen Intern Med* 2005; 20: 3-4.
- Muhammad IA, Jonathan GF. Prolonged gastroparesis after corrective surgery for Wilkie's syndrome: a case report. *J Med Case Reports* 2008; 2: 109.
- Agarwalla R, Kumar S, Vinay A *et al.* Laparoscopic duodenojejunostomy for superior mesenteric artery syndrome. *J Laparoendosc Adv Surg Tech* 2006; 16: 372-3.
- Palanivelu C, Rangarajan M, Senthilkumar R, Parthasarathi R, Jani K. Laparoscopic duodenojejunostomy for superior mesenteric artery syndrome. *J Soc laparoendoscopic Surgeons* 2006; 10: 531-4.
- Samdani PG, Samdani V, Goel A. Superior mesenteric artery compression syndrome. *Indian J Paediatr* 2006; 73: 523-5.
- Kaushik R, Attri AK. Acute Superior Mesenteric Artery Syndrome. *Indian Pediatr* 2003; 40: 1014-15.
- Altman DH, Puranik SR. Superior mesenteric artery syndrome in children. *Amer J Roentgenol* 1973; 118: 104 - 8.
- Selami S, Hayrunisa K, Arzu A, Gulsen E, Haluk GB. Incomplete duodenal obstruction in a newborn. *Indian J Paediatr* 2006; 73: 364-6.
- Konen E, Amitai , Apter S *et al.* CT Angiography of Superior Mesenteric Artery Syndrome. *Amer J Roentgenol* 1998; 171: 1279 - 81.
- Laffont I, Bensmail D, Rech C, Prigent G, Loubert G, Dizien O. Late superior mesenteric artery syndrome in paraplegia: case report and review. *Spinal Cord* 2002; 40: 88-91.