

Simultaneous occurrence of hematometrocolpos and consecutive pregnancies in uterine didelphys : a case report

A Rana,¹ G Gurung,¹ B Manandhar¹ and RK Ghimire²

¹Department of Obs/Gynae and ²Department of Radiology, TU Teaching Hospital, Institute of Medicine, Kathmandu, Nepal

Corresponding author: Dr. Prof Ashma Rana, T.U. Teaching Hospital, PO Box No 3578, Kathmandu, Nepal,
e-mail: ashmarana@hotmail.com

ABSTRACT

Hematometrocolpos drained abdominally at laparotomy done, with suspicion of an ovarian torsion in an adolescent with ipsilateral renal agenesis, was eventually rediscovered to have in coexistent uterine didelphys in a 25 year P₃+0 at the time repeat caesarean for breech in the event of third parturition, complicated by partum hemorrhage as in all her previous delivery (first vaginal delivery and retained placenta, second caesarean for obstructed labor by non pregnant half of didelphic uterus). This illustrates how simultaneous occurrence of hematometrocolpos can go unnoticed although there was every reason for this condition not to go unrecognized for the simple fact of hemivaginal obstruction and hematometra with ipsilateral renal agenesis (on the left side) unaffacting the consecutive pregnancy in the other uterus.

Keywords: hematometrocolpos, soft tissue obstruction, uterus didelphys.

INTRODUCTION

Unilateral hematometrocolpos and ipsilateral renal agenesis has been useful guide in making the diagnosis of didelphys uterus, one with hemivaginal obstruction.^{1,4}

Hydrometrocolpos simultaneously occurring with pregnancy although have been reported in didelphic uterus, detection of solitary hematometra has only been mentioned in the rudimentary horn of a unicornuate uterus in a 30 year old presenting with pelvic mass, increasing dysmenorrhea and progressive right lower-quadrant pain surprisingly after cesarean section.^{5,6}

It may be surprising however, but hematometrocolpos resulting from imperforate vagina have gone unnoticed for long time when, one of the didelphys uteri is normally menstruating or harboring pregnancies consecutively as this case reports . Here hemi hematometrocolpos due to obstructed hemi vagina by obliquely placed transverse vaginal septum in one of the uterus didelphys coexisted with pregnancies occurring consecutively in the other uterus simultaneously.

CASE

25 year old G₃P₂L₁ attended our antenatal clinic at 28 weeks of pregnancy. She had been seeking care in other hospitals in previous pregnancies and delivery and had for the first time attended our hospital for antenatal care. There were two scars in lower midline, one was caesarean, and the other was laparotomy scar which had significant history.

To begin, she had menarche at 15 and was having normal menstruation for 2 years after which she started

experiencing cyclical pain for 3-4 month that progressed to acute abdominal pain one day and was taken to emergency, when an ultrasound detected a left sided pelvic mass and the absence of ipsilateral kidney on the same side of the mass. Thinking of a twisted ovarian cyst, laparotomy was done, instead hematometra was seen in one of the uterine horn. About 500 ml of blood was drained making a small stab incision. Three weeks later a diagnosis of complete vaginal septum in the left side was made after examination under anesthesia.

Regarding obstetric history, she was married within the next 6 months and was soon able to conceive at the age of 17. But this time she was supervised in a different hospital.

At 40 weeks of first pregnancy there was sudden loss of fetal movement following which she went into spontaneous labor and delivered a stillborn average birth weight baby boy vaginally, unfortunately complicated by retained placenta and postpartum hemorrhage (PPH). Manual removal of the placenta was done and 3 units of blood was transfused.

The second pregnancy occurred just after 8 months. There was spontaneous onset of labor at 41 weeks of pregnancy and labor was augmented. After 12 hours soft tissue obstruction was noted for which caesarean was done and a live baby weighing 3100 Gms was delivered. Primary postpartum hemorrhage occurred and 2 units of blood were transfused. The type of uterine anomaly was not documented in the discharge summary.

At the time of first antenatal examination of third pregnancy in our hospital, two lower midline scars

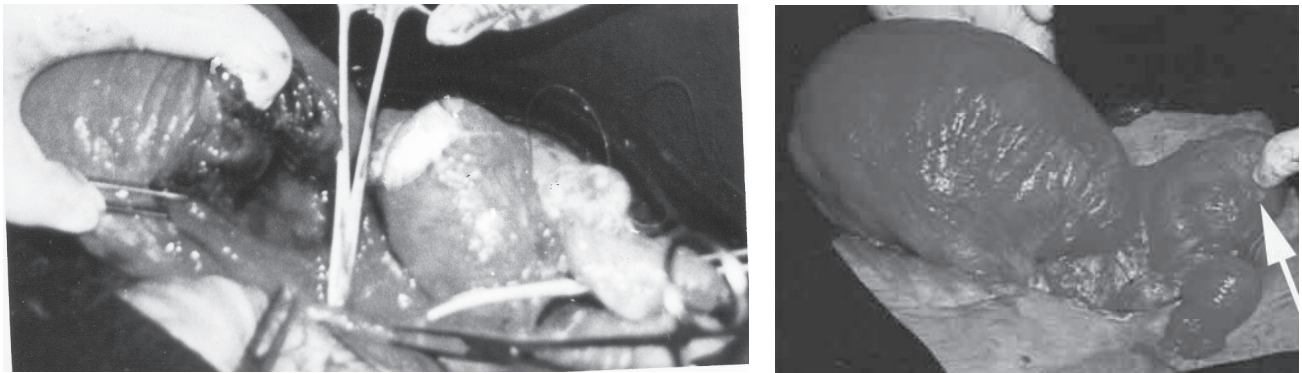


Fig. 1 a/b uterus didelphys: right one has been cut open in the lower segment (a) and repaired (b), the left the uterus accompanied by swollen left tube and ovary has been pointed by an arrow.

attributing to laparotomy done for drainage of hematometra and caesarean sections were noted. She was regularly followed in the antenatal clinic up and was admitted at 36 weeks of pregnancy for an elective caesarean and bilateral tubal ligation for breech presentation and suspected uterine anomaly.

On opening the abdomen there were two uteri with intervening thick connective fibrous band in between them. On the left side was a non pregnant uterus, approximately measuring 18 x18x16 (fig1) which was lying anterior and to the left side of the pregnant uterus.

A live baby boy presenting as frank breech, weighing 3400gms was extracted out by lower segment caesarean section and bilateral tubal ligation was done. There was atonicity of the uterus leading to primary postpartum hemorrhage resulting in excessive blood loss amounting to more than 1500 ml. which was managed by oxytocic

infusion and two units of blood transfusion (hemoglobin level 6.7 gm %).

At the end of surgery during the time of vaginal toileting, a single vagina was seen. Ultrasonogram done prior to discharge showed right uterus to be markedly distended with blood (Fig 2). The puerperal post caesarean section uterus had thin endometrial lining.

After 8 months of delivery, pelvic examination found complete uterine involution of the parturient right uterus while the left uterus enlarged to the size 10-12 weeks of pregnancy. The vagina, now appeared single with soft boggy appreciated high up in the left lateral vaginal wall, having extension almost close to urethra, rightly diagnosed by MRI to be hematometrocolpos (Fig.3 and 4)

Four years post caesarean when summoned for the treatment of hematometrocolpos which stands the risk of transformation to pyocolpos and slim possibility of the development of sepsis, the patient walked away reluctant to undergo any kind minor or major surgery.

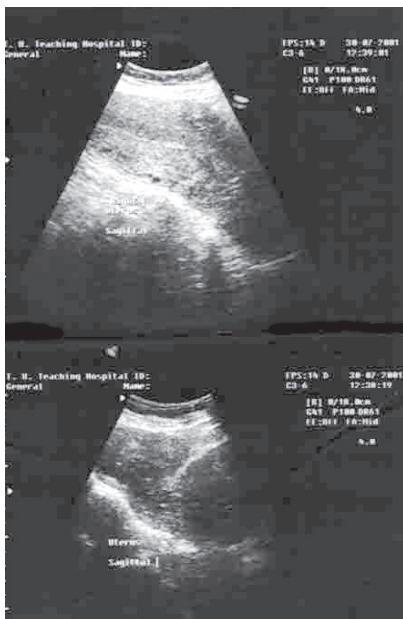


Fig 2. TVS picture taken in 4th postpartum day, showing right uterus with thin endometrial lining and cervix; the left uterus with imperforated upper vagina with blood collection lower down up to the urethra.

DISCUSSION

The fertility and conceptions in this didelphic uterus despite the collection of blood in the one of the uterus (hematometrocolpos) was seen to be equally as good as any other normal uterus. This is because the vagina was apparently single and the obstruction by vaginal septum was present only in the upper part of the left uterus, such that the seminal pool all the time had an access to only one uterus, seat of three consecutive term pregnancies.

The contra lateral uterus with hematometra due to hemivaginal obstruction lay dormant during pregnancies because of amenorrhea, once obstructed the progress of labour. While post partum hemorrhage repeatedly occurred with retained placenta in the first pregnancy.

The hematometra and the related boggy produced by blood collection must have been missed on account of a single capacious vagina from high up oblique placement of vaginal septum. Similarly lateral pouch has

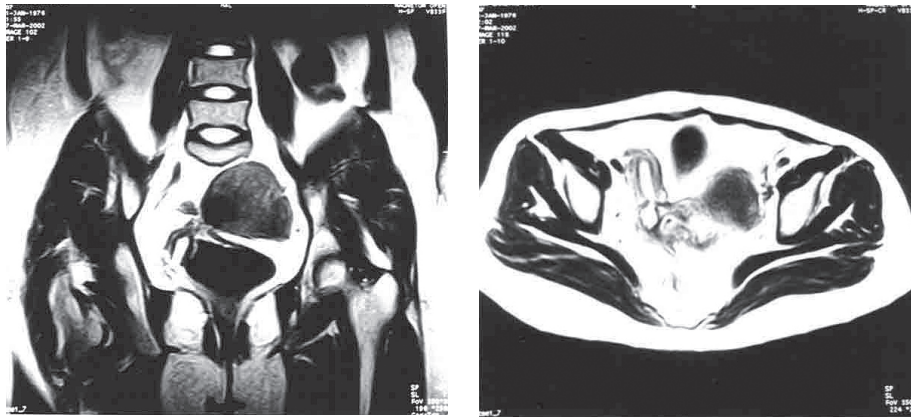


Fig 3 and Fig 4. T2 weighted sagittal / coronal section showing extremely deviated right uterus with hyperintense endometrium whereas the right vagina is compressed and displaced by hematocolpos.

resulted from progressive blood collection, above the level of obliquely placed residual/partial septum ending high up.

There are reports of innocuous recurrent vaginal bleeding from non pregnant (patent) didelphic uterus during pregnancy. Or pregnancies have alternated in both of them or occurred simultaneously in either of the uterus didelphys in form of twin/ triplets.⁷⁻¹² Meanwhile persisting dormant hematometrocolpos coexisting with the consecutive term pregnancies in the other busy uterus has made this case very unique.

Today there are options for non invasive and sophisticated management where the septum can be removed vaginally from below under the laparoscopic guidance and hopefully one day we would be able to make her happy.¹²⁻¹⁵

In conclusion a didelphic uterus with ipsilateral renal agenesis in the side of obstructed hemivagina and hematometrocolpos which has persisted for more than a decade; simultaneously coexisting at times with pregnancies in the busy uterus consecutively thrice and up to term ending in two caesarean live births is a rare occurrence after abdominal drainage of hematometra which mostly predisposes to endometriosis and infertility.

REFERENCES

1. Zurawin RK, Dietrich JE, Heard MJ, Edwards CL. Didelphic uterus and obstructed hemivagina with renal agenesis: case report and review of the literature. *J Pediatr Adolesc Gynecol* 2004; 17: 137-41.
2. Tanaka Y, Kurosaki Y, Kobayashi T et al. Uterus didelphys associated with obstructed hemivagina and ipsilateral renal agenesis: MR findings in seven cases. *Abdo Imaging* 1998; 23: 437-41.
3. Takagi H, Matsunami K, Noda K, Furui T, Imai A. Magnetic resonance imaging in the evaluating of double uterus and associated urinary tract anomalies: a report of five cases. *J Obstet Gynaecol* 2003; 23: 525-7.
4. Shibata T, Nonomura K, Kakizaki H, Murayama M, Seki T, Koyanagi T. A case of unique communication between blind-ending ectopic ureter and ipsilateral hemi-hematocolpometra in uterus didelphys. *J Urol* 1995; 153: 1208-10.
5. Russ PD, Zavitz WR, Pretorius DH, Manco Johnson ML, Rumack CM, Pfister RR, Greenho. Hydrometrocolpos, uterus didelphys, and septate vagina: an antenatal sonographic diagnosis. *J Ultrasound Med* 1986; 5: 211-3.
6. Chang CY, Chang SY, Changchien CC, Lui CC, Huang HW. Hematometra of the rudimentary horn of a unicornuate uterus resulting from cesarean section. *Amer J Obstet Gynecol* 2001; 185: 1263-4.
7. Singh N, Giannopoulos T, Brown DC et al. Innocuous recurrent vaginal bleeding during pregnancy in a patient with uterus didelphys. *J Obstet Gynaecol* 1998; 18: 592.
8. Manzella A, Filho PB. Hydrocolpos, Uterus didelphys and septate vagina in association with ascites: Antenatal sonographic detection. *J Ultrasound Med* 1998; 17: 465-8.
9. Giannopoulos T, Croucher C. Successful consecutive pregnancies in separate horns of a uterus didelphys. *J Obstet Gynaecol* 2004; 24: 314.
10. Brown DC, Nelson RF. Uterus didelphys and double vagina with delivery of a normal infant from each uterus. *Canadian Med Assoc J* 1967; 96: 675-7.
11. Nohara M, Nakayama M, Masamoto H, Nakazato K, Sakumoto K, Kanazawa K. Twin pregnancies in each half of a uterus didelphys with a delivery interval of 66 days. *Brit J Obstet Gynaecol* 2003; 110: 331-2.
12. Chang LW, Chang CH, Yu CH, Chang FM. Prenatal diagnosis of a triplet pregnancy complicated with one acardius in a patient with didelphys uterus using three-dimensional ultrasound. *Prenat Diagn* 2003; 23: 172-3.
13. Cicinelli E, Romano F, Didonna T, Schonauer LM, Galantino P, Di Naro E. Resectoscopic treatment of uterus didelphys with unilateral imperforate vagina complicated by hematocolpos and hematometra: case report. *Fertil Steril* 1999; 72: 553-5.
14. Sherer DM, Rib DM, Nowell RM, Perillo AM, Phipps WR. Sonographic-guided drainage of unilateral hematometrocolpos due to uterus didelphys and obstructed hemivagina associated with ipsilateral renal agenesis. *J Clin Ultrasound* 1994; 22: 454-6.
15. Hinkley MD, Milki AA. Placement of an oblique septum that was excised vaginal route: Management of uterus didelphys, obstructed hemivagina and ipsilateral renal agenesis. A case report. *J Reprod Med* 2003; 48: 649-51.