

Seasonal hyper acute pan uveitis - recent scenario in Nepal

A Manandhar,¹ G Paudel,¹ CK Rai,² SK Rai,² R Gurung¹ and S Ruit¹

¹Tilganga Eye Center, Gausala, ²Nat'l Inst Trop Med & Public Health/Shi-Gan Health Foundation, Narayangopal Chowk, Kathmandu, Nepal

Corresponding author: Dr. Anu Manandhar, Post Box 561, Tilganga Eye Center, Gausala, Kathmandu, Nepal, e-mail: uveitis_tec@yahoo.com

ABSTRACT

Seasonal hyperacute panuveitis (SHAPU), characterized by an unusual form of unilateral severe hyper acute diffused intraocular inflammation, is one of the mysterious eye diseases of which the definite cause and treatment remains yet to be found out. In this study, a total of six cases were included. Aqueous and vitreous samples were subjected to direct microscopy and culture (bacterial or fungal). Of the six cases included, two yielded *Streptococcus pneumoniae* and one *Acinetobacter* sp. on culture. All three culture positive samples showed pus cells in direct microscopic examination (gram stain). All cases were subjected to vitrectomy and intravitreal antibiotic and steroid injection, along with oral antibiotics and steroid. Five cases were also treated with antiviral agent. After treatment four cases showed reversal of hypotony and three cases recovered some vision.

Keywords: SHAPU, moth, inflammation, aqueous, vitreous, Nepal.

INTRODUCTION

Seasonal hyperacute panuveitis (SHAPU), the unusual form of diffused intraocular inflammation predominantly affecting the children, reported only from Nepal^{1,2} and has been presumed to be associated with a kind of white Tussock moth.¹ However, moth (*Megalopygidae*, *Arctuidae* and *Noctuidae*) experiments did not prove this presumption.² Though first noted as endophthalmitis by Malla,¹ Upadhyay *et al*² were the first to describe this strange disease in detail naming the condition as SHAPU. Malla,³ however, still prefers to call it "seasonal endophthalmitis". The unique characters of the disease include unilateral involvement, occurrence in two year cycle during autumn season (September to December), no geographical boundaries,² hyper acute course, and predilection for children,¹ and no gender predilection.^{1,4}

According to Upadhyay *et al*,² sudden onset of redness and leukocoria in one eye with minimal pain in and around the affected eye and sudden loss or drastic diminution of vision are the common presenting symptoms of this disease. Fibrinoid anterior chamber (AC) reaction, hypopyon, shallowing of AC, collection of fibrinoid exudates in the crypts of muddy iris, retrolental white deposits obscuring retinal view, drop in intraocular pressure (IOP) leading to severe hypotony (malignant hypotension) are the common signs seen so far. However, no reports on how the retina looks behind the dense vitreous opacity in the active stage of the disease are available. Microbial investigation of aqueous drawn from the cases failed to grow organisms. Aqueous injected into the AC, sub-conjunctiva and into the pinnae of experimental animals also failed to produce any kind

of intraocular inflammation. However, Kathil⁵ from India has reported the *Varicella zoster virus* (VZV) in the aqueous of a case presumed to be SHAPU by immunofluorescent microscopy.

Various therapies like oral steroid, periocular steroids, azathioprine had been tried but without success.² However, early vitrectomy reportedly helped to restore some vision or at least to preserve the eye ball.³ On the other hand, iv antiviral and antibiotic together with oral steroid could restore the visual acuity to 6/6 without any surgical intervention in one case⁵

The present study attempted to find out whether the bacteria might be the causative agent of SHAPU cases, to describe the look of retina in the active stage of disease.

CASE REPORTS

Six cases (aged 3 to 16 years) of hyperacute endophthalmitis consistent with SHAPU seen at Tilganga Eye Center in the autumn of 2005 were studied. In each and every case, detail medical history and the history of moth contact or moth in the environment was taken. All cases presented with mild pain (but only at the onset of disease), fluffy, non cohesive AC exudates filling the crypts of muddy iris, hypopyon (Fig. 1). Two cases had no perception of light while four cases had inaccurate projection of rays at presentation. Only one case presented with leukocoria and the rest with a dense fibrinoid membrane over the bound down pupil not allowing the view of the lens or beyond. Hypotony at presentation was found only in two cases. One case had mild stromal edema with diffused stromal infiltration of white blood cells. Three cases gave the h/o abundant

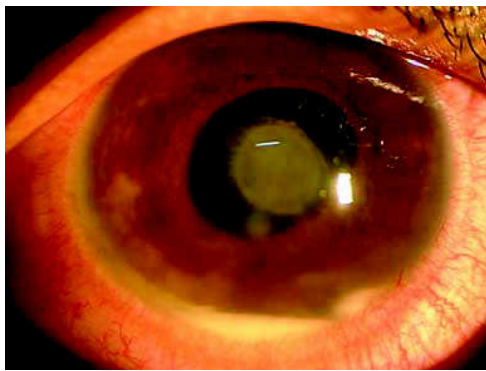


Fig. 1. Anterior segment of eye.

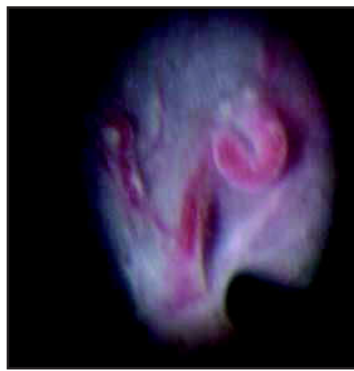

Fig. 3. Retina seen peroperatively



Fig. 2. Vitreous sample collected.

white moths in the environment; five patients were sure about no moth contact, while one was not sure.

All cases were subjected to surgical intervention (vitreous or aqueous tap, parsplana vitrectomy with or without lensectomy, with intravitreal and s/c vancomycin, amikacin and dexamethasone injection), earliest on the day of presentation and latest on the fourth day of presentation. Intraoperatively, greenish yellow colored vitreous exudate with consistency like that of lens cortical matter, rather than being pus like, was seen in all cases (Fig. 2). In three cases, retina was seen intraoperatively after clearing the vitreous. It showed dilated tortuous segmented sausage like arteries and veins, hyperemic optic nerve head, pale whitish retina with fluffy white exudates over it (Fig. 3).

Vitreous of all cases and aqueous of few cases were subjected to microbiological study. Samples were transported to the laboratory of Nat'l Institute Tropical Medicine and Public Health/Shi-Gan Health Foundation without delay. Microbiological investigations were done following standard microbiological procedures (for bacteria and fungi). Investigations for viruses and parasites were not done. Of the six cases included, two yielded *Streptococcus pneumoniae* and one *Acinetobacter* sp. on culture. All three culture positive samples showed pus cells in direct microscopic examination (gram stain) (Table-1). Other investigations (CBC, ESR, urine routine) could be done only in three cases and were within normal limits.

All cases were treated with a course of oral antibiotic (cephalexin in four cases

and ciprofloxacin in two cases) and prednisolone as well as topical prednisolone acetate, vancomycin and amikacin. In three cases, the administration of oral prednisolone was early (ranging from day one to day three of the presentation) whereas in remaining three cases it was initiated late (on the 2nd week from the presentation). Five cases were treated with an acyclovir (iv or oral along with or without intravitreal injection).

These six cases came from each of Kaski, Nuwakot, Kathmandu, Bhaktapur, Sindhupalchok and Dolakha district. First case was seen on September 12 and the last case on October 27, 2005. Duration of disease on presentation ranged from 4 days to 2 weeks.

Upon follow up (for two to six weeks) reversal of hypotony could be seen in four cases, of which three showed fundus also. Of these three cases with clear fundus, restoration of vision could be seen in one case (had 6/24 aphakic correction) while in other two, vision could not be recovered (one of these two cases developed nasal rhegmatogenous retinal detachment (RRD) on the 12th postoperative day, for which revitrectomy with 240 band buckle and silicone oil was performed). The fourth one, despite of hazy view of fundus recovered vision up to counting of fingers close to face. Remaining other two cases unfortunately continued to be hypotonous.

DISCUSSION

SHAPU, the unusual ocular problem reported only from Nepal^{1,2} is presumed to be associated with a white *Tussock* moth.¹ However, moth experiments did not prove this

Table-1: Microscopic and bacteriological findings of the six SHAPU cases studied

N	Aqueous			Vitreous		
	Gram stain	Giemsa stain	Culture	Gram stain	Giemsa stain	Culture
1	NAD*	NAD	Sterile	Gram positive cocci & pus cells few	NAD	Strept. pneumoniae
2	ND**	ND	ND	NAD	NAD	Sterile
3	ND	ND	ND	Pus cells few	PMN few	Sterile
4	ND	ND	ND	Pus cells few	PMN few	Sterile
5	ND	ND	ND	Gram positive cocci & pus cells plenty	PMN few	Strept. pneumoniae
6	ND	ND	ND	Gram negative bacilli & pus cells few	PMN few	Acinetobacter sp.

*NAD=No abnormality detected; **ND=Not done due to the sample quantity not sufficient No fungus detected/grown in all samples studied.

presumption.² Present findings also did not correlate the development of SHAPU with the history of moth contact though three of the six cases mentioned about the presence of moth in the environment; five patients were sure about no moth contact, while one was not sure. Interestingly, the disease occurs in two year cycle during autumn (September to December) of odd or uneven year, and the timing of the disease outbreak included in this series correlated with the previous reports.^{1,2,4}

As has been reported earlier, there is no defined geographical territories for SHAPU.² Patients included in this study also were coming from different districts in Nepal. However, our cases were mainly from hilly districts including Kathmandu Valley.

As has been reported earlier,¹ all patients except one (aged 16 years) were children (14 and less than 14 years of age). No gender predilection observed in our series (males 3 and females 3) was in agreement with previous reports.^{1,4} This indicates that both the sexes are at equal risk of developing SHAPU.

The clinical features on presentation were similar to the findings observed previously.^{1,2,4} However, the granulomatous nature of the disease, previously not described, was seen in fifty percent of the cases in about a month time after the onset of the disease. Interestingly enough, all three cases that developed granulomatous inflammation, were bacterial growth positive (*Strept. pneumoniae* in two and *Acinetobacter* sp. in one on 3rd and 4th weeks, respectively). This finding may indicate that the granulomatous inflammation is associated with bacterial infection. In addition, color and consistency of vitreous exudates, and the retinal findings have also been described for the first time.

Though previous study did not reveal the bacterial association with SHAPU cases,² allergic reaction with moth antigen has also not been proven.² These findings are in support of the demonstration of bacteria in this study. This was further supported by the presence of significant number of pus cells in Gram stained smear and absence of mononuclear cells as well as inclusion bodies in Giemsa stain smear. However, this is too early to draw a conclusion as the sample size was small and, therefore, advocated further study with larger samples size. On the other hand, *Varicella zoster virus* has been demonstrated in one 34 years male SHAPU patient who initially attended Tilganga Eye Centre and later visited Sankar Netralaya in Chennai (India).⁵ Virus detection and good outcome of antiviral treatment⁵ indicated that SHAPU outbreak in the year 2001 could be due to virus. Presently we are also in the process of looking for the viral agents (*Herpes simplex* and *VZV*, *Cytomegalovirus* and *Epstein-Barr virus*) in the samples collected from these patients and stored at -70C.

All six cases were apparently healthy, having no preceding history of any kind of illness or ocular trauma/surgery. However, possibility of endogenous endophthalmitis can not be ruled out.

Considering the clinical findings, first five cases were treated with an anti viral agent (i/v and/or oral and/or intravitreal acyclovir) presuming viral infection. But, based on the bacterial growth (*Strept. pneumoniae*) positivity in two of the vitreous tapped, the sixth case was not subjected to anti viral treatment. The sixth case without anti viral treatment yielded *Acinetobacter* sp. These findings were in contrast to the previous finding; no bacteria were grown in the aqueous.²

The outcome of the vitrectomy in this series was good as has been reported by Byanju *et al.*⁴ Co-incidentally those three cases in which lensectomy was also performed, the outcome either in terms of reversal of hypotony or recovery of vision was better. The possible reason for this could be the fact that due to better visibility, the extensive vitrectomy could be performed in those cases.

Out of the four cases who reversed from hypotony, it turned out that three had received early oral steroid treatment. Furthermore, in this series the use of intravitreal antibiotics (Vancomycin and Amikacin) and steroid (dexamethasone) must have been of additional help.

Present findings, for the first time, are suggestive of bacterial involvement in SHAPU cases. However, as has been mentioned elsewhere, it is too early to make a conclusion. It is, therefore, suggested to carry out a planned systematic study of this mysterious eye disease in large sample size targeting different possible factors involved in the causation of the disease using available recent diagnostic techniques.

ACKNOWLEDGEMENTS

Mr. MK Shrestha, Mr. B Shrestha, Mr. BS Thapa, Mr. B Dahal, Mr. N Patel and Mr. GR Khan provided their help during this study.

REFERENCES

1. Malla OK. Endophthalmitis probably caused by *Tussock* moth. Proceedings first Nat'l Seminar on Prevention of Blindness 1978: 44.
2. Upadhyay MP, Rai NC, Ogg JE, Shrestha BR. Seasonal hyperacute panuveitis of unknown etiology. *Ann Ophthalmol* 1984; 16: 88-44.
3. Malla OK. Sudden blindness in Nepal children (Editorial). *Kathmandu Univ Med J* 2005; 3: 1-5.
4. Byanju RN, Pradhan E, Sapkota YD. Visual outcome of vitrectomy in seasonal hyperacute panuveitis. *Kathmandu Univ Med J* 2003; 1: 121-3.
5. Kathil P, Biswas J, Gopal L. Demonstration of varicella zoster virus in a case of presumed seasonal hyperacute panuveitis. *Indian J Ophthalmol* 2005; 53: 270-2.