

## Experience of newly constructed echocardiography-database with video clips and color still images at the Echocardiography Lab of Nepal Medical College Teaching Hospital

*B Shrestha and S Dhungel*

Department of Internal Medicine, Nepal Medical College Teaching Hospital, Attarkhel, Jorpati, Kathmandu Nepal.

**Corresponding author:** Dr. Baram Shrestha, MD, PhD, Department of Internal Medicine, Nepal Medical College Teaching Hospital, Attarkhel, Jorpati, Kathmandu, Nepal Email: balaramshresthajps@yahoo.com

### ABSTRACT

Reporting system after performing echocardiography is very poor in almost all hospitals of Nepal. Special but simple attempt effort has been introduced to transfer analog video images and color still images of echocardiographic investigation into a desk top computer using a locally available imported video capture system, Snazzi Movie Studio S4. Analog video signals are converted into MPEG2 and still color snaps are converted into JPEG format. Window media player can be used later on to review the video clips. All together 1059 patients including pediatric, adults and geriatric patients underwent echocardiographic evaluation at the Echo-lab of Nepal Medical College Teaching Hospital during 10th January 2007 to 9th May 2008. Age ranged from 2 months to 98 years. Mean±SD was 52.4±18.5 years. Male/female ratio was 0.8:1. More than half of the patients (64.3%) came from Kathmandu. *Brahman/Chhetri* (478, 45.1%), *Tamang, Sherpa* etc 278 (26.3%) and *Newar* (226, 21.3%) were the main echo-users. Elderly age group (>60 yr) comprised of more than one third of the patients (42.0%) followed by the age group of 45-59 yr (27.7%). No abnormality was detected in 133 (12.6%) patients. Valvular heart disease was noticed in more than half of patients (60.7%), followed by diastolic dysfunction (393, 14.0%) and left ventricular hypertrophy (210, 7.5%). This database is not very expensive but demand minimal extra time and energy. It will be a valuable tool to increase diagnostic accuracy and a great resource for academic purpose aiding in the improvement of cardiac care in Nepal.

**Keywords:** Echocardiography, video clips, still images, database.

### INTRODUCTION

Usually video images of echocardiography are stored in video tapes, preferably super video tapes however; digital echocardiography has been developed with lots of advantages over the conventional video tape recording.<sup>1,2</sup> Conversion to digital technology improves efficiency.<sup>3</sup>

In Nepal, however, a very primitive method of data management after performing echocardiography is the usual practice even in the pioneer hospitals like Tribhuvan University Teaching Hospital (TUTH) and the superspeciality hospital like Sahid Ganga Lal National Heart Centre. The recording of the video clips and still images during echocardiography is considered as the wastage of time, energy and material. Hence video images are not recorded in almost all hospitals of Nepal. We have attempted to develop a new database with a permanent storage of the video/audio/ color still images from analog echo machine to a computer with locally available imported software and add the comment of a cardiologist as a report of echocardiography. In our knowledge, this is the first of its kind that has been partly developed and practiced in Nepal in real clinical scenario.

### PATIENTS AND METHODS

Technique of performing transthoracic echocardiography in adult is as per the recommendation of American Society of Echocardiography.<sup>4,5</sup> Liberal use of subcostal and suprasternal echo windows are used when deemed necessary. In pediatric patients, segmental approach of performing echocardiography has been undertaken for the examination.<sup>6</sup> Echocardiography machine used for this study is LOGIQ 400 MD MR3 Version 4.31 (GE).

An attempt has been undertaken to construct a database to keep permanent record of various dimensional measurements, Doppler studies and comment of the cardiologist along with permanent storage of video clips and color still images of the echocardiographic investigation of all patients undergoing echocardiography. Special but simple attempt has been introduced to transfer analog video images and color still images of echocardiographic investigation, into a desk top computer using a locally available imported video capture system, [Snazzi Movie Studio S4: Set up Options (V One Multimedia Pte Ltd, Blk 54 Kallang Bahru # 02-04, Singapore 339 336) (www.snazzie.com) for storing video and still images as clips and snaps.

Analog video output (S video) and audio output are connected with a computer (video output NTSC) and video signals are converted into MPEG2 (full D1, resolution 720X480), audio signals as MPEG1 and still color snaps are converted into JPEG format. Window media player may also be used to review/ observe/show the video clips. Video clips and color snaps are stored into the hard disk/ external hard disk and are regularly transferred to multimedia devices like DVD/CDs. Color LASER print with demonstrative still images, dimensional measurement and report is provided to patients.

Patient information system is developed by a team of local engineers with Microsoft programming tool. Microsoft visual Basic 6.0 was used as a front end. It helps user to input data and other required information. As for storage of user input data, Microsoft Access is used as backend data server.

**RESULTS**

There were altogether 1059 patients undergoing echocardiographic evaluation at the Echo-lab of Nepal Medical College Teaching Hospital (NMCTH) during 10th January 2007 to 9th May 2008. Age ranged from 2 months to 98 years and mean±SD was 52.4±18.5 years. Male/female ratio was 0.8:1.

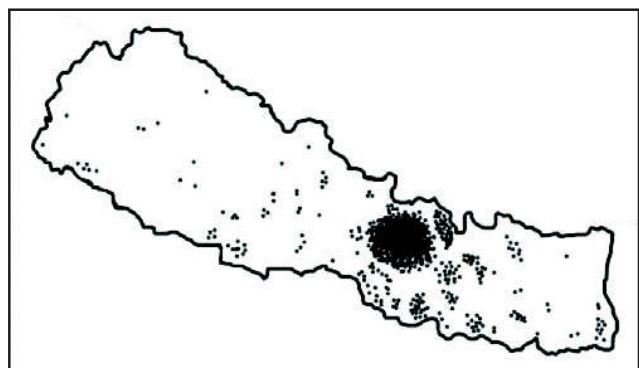


Fig. 1. Map of Nepal showing flow of patients from across Nepal to the Echo-lab of NMCTH. Each dot represents one patient

Fig.1. Map of Nepal showing inflow of patients from across Nepal for undergoing echocardiography at the Echo-lab of NMCTH. One dot represent one patient.

More than half of the patients (64.3%) came from Kathmandu. However, people across the country, visited the Echo-lab for undergoing echocardiographic evaluation at the Echo-lab of NMCTH as shown in Fig.1.

Fig.2. shows the ethnic group wise distribution of the patients attending echo lab of NMCTH.

Almost half of the patients were from *Brahman/ Chhetri* ethnic group 478 (45.1%). *Tamang, Sherpa* etc. 278 (26.3%) and *Newar* 226 (21.3%) were other common users.

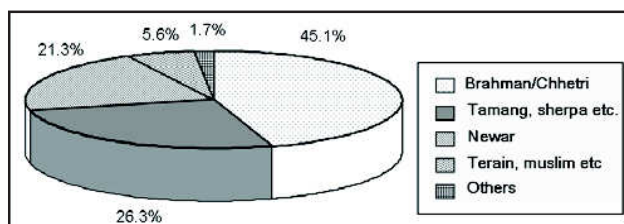


Fig. 2. Pie chart showing ethnic group wise distribution of patients undergoing echocardiography at the Echo-lab of NMCTH

Fig. 3. shows a bar diagram showing age wise distribution of patients.

Elderly people (>60 years) comprised of more than one third of total patients (42%). Greater number of patients underwent echocardiographic examination at the echo-lab of NMCTH as their age increased. This trend is noticeable after 45 years.

Fig. 4. shows a pie chart elaborating the indications of echocardiography in NMCTH.

Echocardiographic evaluation of the heart is practiced more in hypertension (187, 22.6%) and chronic obstructive pulmonary disease/ corpulmonale (161, 19.4%) at NMCTH. Other indications were as shown in the Fig.4. Other cardiac diseases include diseases (excluding hypertension) like rheumatic heart disease, dilated cardiomyopathy, hypertrophic cardiomyopathy, ischemic heart disease, pericardial effusion etc. Other respiratory diseases include diseases (excluding chronic obstructive pulmonary disease, COPD/ chronic corpulmonale) such as pneumonia, pulmonary tuberculosis, interstitial lung disease etc. Other medical diseases include chronic renal failure, pyrexia of unknown origin, diabetes mellitus etc.

Fig. 5. shows lesion wise distribution of patients undergoing echocardiographic study.

Out of total 1059 patients, no abnormality was detected in 133 patients (12.6%). There were 2802 abnormalities detected in remaining 926 patients. As a single patient may have more than one abnormalities, the total number (N = 2802) was more than the total number of patients (n=926).

Fig. 5. shows a pie chart which represents the disease wise distribution of echocardiographic lesions. Valvular

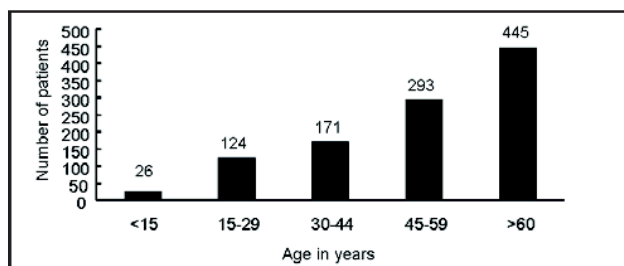


Fig. 3. Bar diagram showing age wise distribution of patients undergoing echocardiography at the Echo-lab of NMCTH.

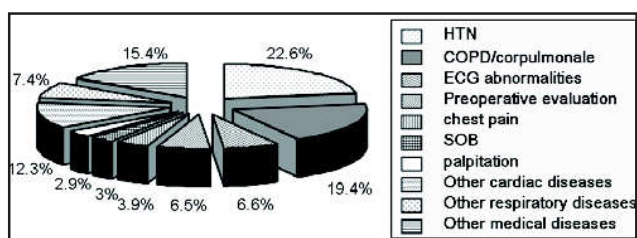


Fig. 4. Pie chart showing indications of echocardiography at the Echo-lab of NMCTH

heart diseases (1702, 60.7%) were the main echo findings. Diastolic dysfunction (Taller A wave in comparison to E wave of left ventricular inflow pulsed wave Doppler) was (393, 14.0%) and Left ventricular hypertrophy (Interventricular septum or posterior wall >1.3 cm) (210, 7.5%) were other common lesions noticed in echo studies. Others include cardiac lesions like aortic aneurysm, left atrial mass etc.

### DISCUSSION

Digital echocardiography has emerged as a better technique of performing echocardiography and quickly replaced the conventional video tape recording/evaluation. It has lots of advantages over the conventional video tape recording.<sup>1-3</sup> Development of Digital Imaging and Communications in Medicine, standard compatible echocardiography machines for storing video images digitally and practice of paper less and tape less echocardiography has not reached the clinical practice in Nepal because these machines are very costly. We have attempted to transfer analog signals from echo machine and stored video clips/ snap shots in digital formats and incorporate them in a locally constructed database.

Video tape interpretation is inferior in terms of cost and time effectiveness in comparison to digital video clips stored.<sup>7,8</sup> To overcome the problem of storage, concept of data compression has been attempted without impairing the image quality.<sup>9</sup> Acceptable image quality preservation by data compression in MPEG4 format, has also been achieved by Umeda *et al*<sup>10</sup> and in MPEG 1 format by others.<sup>11</sup> Similarly compression of still color photographs data without deteriorating the image quality has also been achieved.<sup>12</sup> Our attempt to save the video files in MPEG2 has been carried out as per the availability in the local market. As per the manual of the software, MPEG2 format has better resolution (720X480) than MPEG1 and is DVD compatible.<sup>13</sup> Impression of the writers are that the clarity of video and color still images are quite good and are almost equivalent to the analog images in the monitor of the echo machines.

People have practiced the transfer the video signals from remote hospitals to referral signals and utilized the concept of telemedicine in foreign countries.<sup>14-16</sup> With

this present technique of video clips and snap shots storage and data management, Such practice of telemedicine is now feasible even in Nepal.

The report system with vivid video clips, color snaps are quite useful to explain patients about their disease as well. Academic and research potential of such database is enormous. Development of the Echo library in NMCTH has been achieved in reality now.

After using this present data base and data management system, data of more than one thousand (n=1059) patients are now available for evaluation. Observation of higher number of female patients undergoing echo study is a bit strange in male dominated Nepalese society as male gets better attention and treatment opportunity. The higher number of females patients undergoing echocardiography may be due to higher incidence of valvular heart disease like mitral stenosis in females. Similar finding has been previously reported by Sayami *et al*.<sup>17</sup> Female smokers and exposure to domestic pollution may have resulted in higher number of COPD and cor pulmonale in elderly females. Our data also support this assumption (M:F of patients of chronic cor pulmonale was 63:100 or 0.6:1). It may be one of the contributing causes of higher number of female patients undergoing echocardiographic studies.<sup>18</sup>

Total number of patients undergoing echocardiographic evaluation at Echo-lab of NMCTH is quite good and is almost equal to that of TUTH at the time of peak of its performance.<sup>18</sup> Their report of 20% normal echo study is higher than our finding (12.6%). One contributing factor for a bit higher incidence of normal study in that study may be due to the use of old echo machine without color Doppler at that time.

The more than half of patients (64.3%) attending the Echo-lab of NMCTH were from the capital and it is due to the accessibility. However, there was good flow of patients from across the country. It is especially encouraging to see patients from very remote areas. This could be due to greater trust that has been developed due to the performance of Echo-lab of NMCTH. It may be partly due to the newly constructed and practiced database, lowest fee for echo study in NMCTH, social contact and recommendation by the NMCTH staffs and excellent color LASER printed echo reports which are

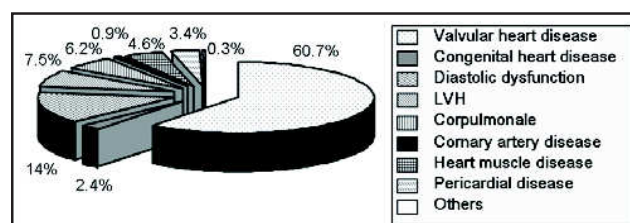


Fig. 5. Pie chart showing lesion wise distribution of echocardiographic findings at the Echo-lab of NMCTH

appealing and attractive to many doctors, patients parties and their relatives.

Higher number of *Brahman/Chhetri* could be due to the increased awareness. Greater number of Mongolian ethnic group such as *Tamang, Sherpa, Gurung* etc may be due to the accessibility of these ethnic groups migrating and densely populating in the surrounding villages nearby NMCTH.

Elderly people (>60 years) comprised about 42.0% of total patients, reflecting higher incidences of cardiac and other diseases in elderly people. The trend was especially apparent after the age of 45 years, when several chronic diseases like hypertension, diabetes, ischemic heart disease starts manifesting.

As shown in Fig 4, echocardiography has been accepted as a reliable measure of assessing the cardiac function in a wide range of patients for various indications. Many times, it has been used as a routine test probably because of the availability of the service. Increased social awareness in the capital may have resulted in many educated people voluntarily attending our Echo-lab for an informal general health checkup. This practice should open the management of NMCTH to open general health checkup package to better channel such patients to undergo various tests and procedures.

Higher number of corpulmonale, left ventricular hypertrophy and diastolic dysfunction may mean the possibility of higher incidence of corpulmonale and hypertension in the attending patients.

After construction and practice of this new database, the authors have acquired strong belief and confidence to recommend this database for the clinical use in all medical institutions or at least the teaching hospitals to improve diagnostic accuracy and academic performance.

This database with digital video clips, color still photographs and comments is not very expensive but demands some extra time and energy. It will be invaluable resource for academic and research purposes. Uplifting report system of echocardiography in almost all hospitals of Nepal is a belated endeavor which must be undertaken if cardiac care is to be improved in dedicated cardiac care centers, teaching hospitals and general hospitals.

#### ACKNOWLEDGEMENTS

We are greatly indebted to Er. SS Basnet, (Electronics and communication) from Medi Serve Enterprises, Kathmandu, Nepal and his team, for his endeavor to transfer video/audio signals and color still images to computer and construct a database for the Echo-lab of NMCTH. We would also like to thank Dr. P Kafle, lecturer of the Community Medicine department of NMC and Ms. M Aryal, system incharge of CMI section of NMC, for their cooperation in constructing one figure.

#### REFERENCES

- Schmailzl JG, Ormerod O, Editors. Ultrasound in Cardiology. 1st ed. Berlin: Blackwell Science 1994; 137-44.
- Feigenbaum H, Armstrong WF, Ryan T. Feigenbaum's Echocardiography: The digital echo laboratory. 6th ed. Philadelphia: Lippincott Williams and Wilkins 2005; 70-5.
- Mathewson JW, Dyar D, Jones FD *et al*. Conversion to digital technology improves efficiency in the pediatric echocardiography laboratory. *J Amer Soc Echocardiogr* 2002; 15: 1515-22.
- Schmailzl KJG. Conventional Echocardiography: Examination Procedure, Fundamental measurement and Assessment Tasks. In. Schmailzl JG, Ormerod O (Eds). Ultrasound in Cardiology. 1st ed. Berlin: Blackwell Science 1994; 49-86.
- Oh JK, Seward JB, Tajik AJ. The Echo Manual. 3rd ed. New Delhi: Lippincott Williams and Wilkins 2006; 7-28.
- Feigenbaum H, Armstrong WF, Ryan T. Feigenbaum's Echocardiography: Congenital Heart Diseases. 6th ed. Philadelphia : Lippincott Williams and Wilkins 2005; 559-636.
- Haluska B, Wahi S, Mayer-Sabik E, Roach-Isada L, Baglin T, Marwick TH. Accuracy and cost- and time-effectiveness of digital clip versus videotape interpretation of echocardiograms in patients with valvular disease. *J Amer Soc Echocardiogr* 2001; 14: 292-8.
- Mohler ER 3rd, Ryan T, Segar DS, Sawada SG, Fineberg NS, Feigenbaum H. Comparison of digital with videotape echocardiography in patients with chest pain in the emergency department. *J Amer Soc Echocardiogr* 1996; 9: 501-7.
- Badano LP, Dall'Armellina E, Bordin P *et al*. Feasibility and clinical value of "intelligent" compression and digital storage of transthoracic echocardiograms in day-to-day practice. *Italian Heart J* 2001; 2: 782-8.
- Umeda A, Iwata Y, Okada Y *et al*. A low-cost digital filling system for echocardiography data with MPEG4 compression and its application to remote diagnosis. *J Amer Soc Echocardiogr* 2004; 17: 1297-303.
- Spencer K, Solomon L, Mor-Avo V *et al*. Effects of MPEG compression on the quality and diagnostic accuracy of digital echocardiography studies. *J Amer Soc Echocardiogr* 2000; 13: 51-7.
- Karson TH, Chandra S, Morehead AJ, Stewart WJ, Nissen SE, Thomas JD. JPEG compression of digital echocardiographic images: impact on image quality. *J Amer Soc Echocardiogr* 1995; 8: 306-18.
- V One Multimedia Pte Ltd. User's Manual: Snazzi Movie Studio S4. Singapore 2003.
- Sable CA, Cummings SD, Pearson GD *et al*. Impact of telemedicine on the practice of pediatric cardiology in community hospitals. *Pediatrics*. 2002; 109: E3.
- Mantero A, Catena E, Tarelli G *et al*. Teleconsulting in echocardiography using a standard cable on HDSL. *G Italian Cardiol* 2007; 8: 168-75.
- Cotton JL, Gallaher KJ, Henry GW. Accuracy of interpretation of full-length pediatric echocardiograms transmitted over an integrated services digital network telemedicine link. *South Med J* 2002; 95: 1012-6.
- Sayami A, Shrestha B. Mitral Stenosis in TU Teaching Hospital. *J Inst Med (Nepal)* 1993; 15: 284-9.
- Sayami A, Shrestha B. Critical Care: Manual of ICU and CCU of TU Teaching Hospital. JICA Medical Education Project, Kathmandu 1995: 5-11.