

## Sphenoid sinus mucocele with blindness: A rare presentation

*BK Sinha and P Adhikari*

Department of ENT and Head and Neck Surgery, T.U. Teaching Hospital, Kathmandu, Nepal

**Corresponding author:** Prof. Bimal K. Sinha, Department of ENT and Head and Neck Surgery, T.U. Teaching Hospital, Kathmandu, Nepal. Email: ent@healthnet.org.np

### ABSTRACT

Isolated sphenoid sinus mucocele is a rare entity. Here we report a case of isolated sphenoid sinus mucocele in a 9 years old girl presenting with unilateral blindness and without any sinonasal complaints. C.T. scan revealed an isolated sphenoid sinus mucocele which was managed endoscopically. A brief review of literature is also included.

**Keywords:** Sphenoid sinus mucocele, blindness.

### INTRODUCTION

Isolated involvement of sphenoid sinus is a rare entity. The anatomical location of the sinus makes early diagnosis of any kind of its pathology difficult. Pathologies involving isolated sphenoid sinus include inflammatory disease like sinusitis, tumors (benign or malignant), mucocele, fungal diseases and cerebrospinal fistula. The close proximity of optic nerve to the sinus makes it very vulnerable to get involved. Lack of standard clinical picture and need of expensive imaging modalities makes this a difficult condition to diagnose and manage. However urgent surgical management is mandatory if sphenoid sinus pathology is suspected to avoid untoward and irreversible complications like blindness.

### CASE REPORT

A 9 year old girl was referred from Department of Ophthalmology to the ENT Out Patient Department of Tribhuvan University Teaching Hospital, Kathmandu, Nepal, with a history of progressive loss of vision of her right eye since 9 months, leading to complete unilateral loss of vision for the past 4 months and progressive right eye proptosis for 3 months. There was no history of pain, headache, redness of eyes, epiphora, diplopia, nasal obstruction, rhinorrhoea, epistaxis, loosening of tooth, trismus, and trauma or sinus surgery.

On examination she was conscious, vitals and her higher mental functions were normal. Anterior rhinoscopy revealed no abnormality. Rigid nasoendoscopy was also performed which did not reveal any pathology or presence of any mass within her nasal cavities or nasopharynx. Eye examination revealed non axial proptosis of her right eye with normal extraocular movement, dilated pupil, with no perception of light and absence of light reflex. There was no other neurological deficit. Her left eye was normal.

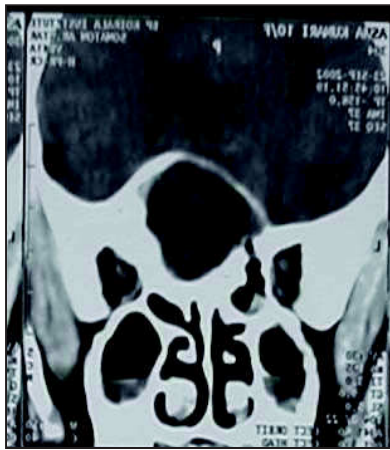
Contrast enhanced CT scan of her nose and paranasal sinuses showed a dilated sphenoid sinus with its eroded right lateral wall and the bony fragments pressing upon the right optic nerve. The interior of the sinus had a homogenous opacity consistent with sphenoid sinus mucocele. (Fig. 1 and 2). The patient underwent an endoscopic transnasal transethmoidal sphenoidotomy under general anaesthesia. Dark brown fluid drained from the sphenoid sinus. On visualization of the interior of the sinus, pulsatile dura was visible on the right side and roof of the sinus. No attempt was made to remove the cyst wall and the cavity was loosely packed with BIPP. (Fig. 3). The pack was removed after 48 hours.

Follow up after 1 month revealed no significant reduction in proptosis, no change in her vision or light perception and nasoendoscopy showed minimal crusting in middle meatus and ethmoid. After three months of surgery her proptosis had decreased, but there was no change in vision or its response to the light. Nasoendoscopy revealed well epithelialized cavity with no crusting.

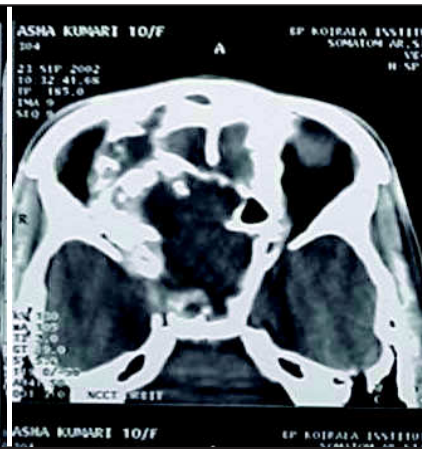### DISCUSSION

Sphenoid sinus is the least common site of mucocele of all paranasal sinuses and represents less than 2.0% of all paranasal sinus mucoceles.<sup>1</sup> It is very rare in children, especially in less than 12 years of age when pneumatization of the sphenoid sinus is completed.<sup>2</sup>

The common presenting symptoms mentioned are progressively worsening headache, visual loss, decrease visual acuity, visual field defect, diplopia, rhinorrhoea, and nasal congestion.<sup>3</sup> However, some patients even present with acute onset of significant visual impairment and headache.<sup>2</sup> Reports of sudden bilateral blindness also available.<sup>4</sup> Our patient did not give any history of headache may be because there was a very slow progression of the size of the swelling which is evident



**Fig.1.** Showing homogenous opacity consistent with sphenoid sinus mucocoele



**Fig. 2.** Showing homogenous opacity consistent with sphenoid Sinus mucocoele

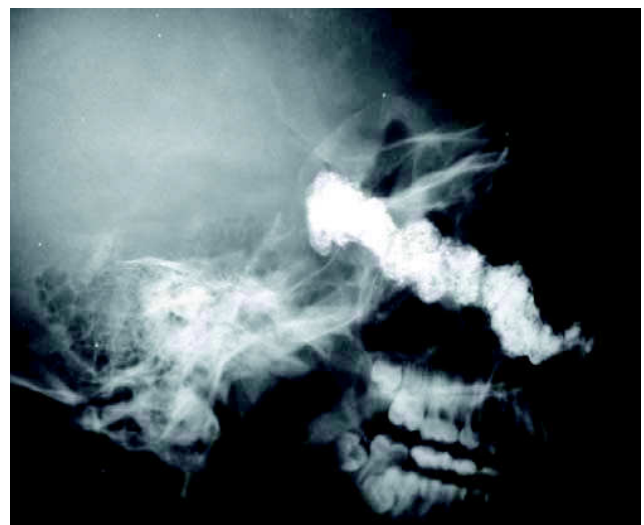by her progressive loss of vision. It has been found that majority of the patients with isolated sphenoid sinus disease usually present at Departments other than otolaryngology.<sup>5</sup> Our case also had first presented at the Department of Ophthalmology. In fact the type of ocular symptom largely depends on the pathology. Okuda *et al*<sup>5</sup> in his analysis of 44 cases of isolated sphenoid sinus lesion, found that 32 patients had inflammatory disease, 8 mucocoele, 1 benign tumour and 3 malignant tumours. The most common symptoms were headache in 59.0% followed by ocular symptoms in 27.0%. Ocular symptoms included ocular pain in 60.0% of those with inflammatory disease, visual disturbance in 63.0% of those with mucocoele and diplopia in all of those with neoplasms. Patients with headaches and diplopia were found to have a high ratio of malignant neoplasms.<sup>5</sup> Heybroek *et al* have also reported a case of sphenoidal mucocoele presenting with bilateral visual disturbance along with pituitary gland dysfunction but without nasal or sinus complaints.<sup>6</sup> Similarly a rare case of acute third cranial nerve palsy was also reported<sup>7</sup> and rarely they may also present with multiple cranial palsies (II, III, IV, VI). A gradual drop of vision is caused by circulatory disorders of the optic nerve owing to pressure by the mucocoele. A rapid loss of vision is generally the result of spread of infection and inflammation from the mucocoele to the optic nerve.<sup>8</sup> Diagnosis is usually made by history, physical findings and imaging modalities.

The etiology of mucocoeles is not clear, however, prior sinus diseases, allergic history have been implicated.<sup>9</sup> The CT scan features of mucocoele will show a homogenous, non enhancing, expansile sinus masses completely filling the potential sinus cavity expanding or remodeling surrounding bone margins. Mucocoeles generally do not enhance with contrast, but acutely inflamed mucopyocoeles may show enhancement.<sup>10</sup> On

MRI, the signal intensity of mucocoeles varies in accordance with fluid content, presence of a proteinaceous component or hemorrhage. They usually have low signal intensity on T1 weighted images and a signal void on T2 weighted image sequence due to inspissated debris. Differential diagnosis of such lesions include necrotic primary adenoma in cases with significant intrasellar extension, craniopharyngioma, chordoma, plasmacytoma, osteoma, osteoblastoma, basal cell and squamous cell carcinoma, rhinolith, polyps, and fibrous dysplasia.<sup>1</sup>

An external surgical approach was used in the past for the management of sphenoid mucocoele before endoscopic surgery became popular. But now-a-days, marsupialization by partial removal of the anterior and inferior walls of the mucocoele via an endoscopic endonasal approach has been mentioned to be the treatment of choice for various reasons.<sup>11</sup> This approach prevents recurrences and complications in most of the cases. Early intervention may result in improvement of visual symptoms as well<sup>12</sup> but the prognosis is poor in patients who have already lost their eyesight before undergoing any kind of surgical intervention. Early detection of the condition can prevent development of serious and lifelong complications

Sphenoid sinus mucocoele even though rare, must be kept in mind in cases presenting with visual disturbances, proptosis and headache. Prompt investigation, diagnosis and early intervention in the form of surgery is required to avoid permanent visual disability.



**Fig. 3.** Sphenoid along with nasal cavity was loosely packed with BIPP

**REFERENCES**

1. Darouassi Y, Righini CA, Reyt E. Mucocoeles of the sphenoid sinus: a report of four cases and review of the literature. *B-ENT* 2005; 1: 181-5.
2. Haloi AK, Ditchfield M, Maixner W. Mucocoeles of sphenoid sinus. *Pediatr Radiol* 2006; 36: 987-90.
3. Strek P, Zagólski O, Skądzień J, Oleć K. Sphenoid sinus mucocele with intracranial extension managed under endoscopic guidance. A report of an extremely rare case: *B-ENT* 2007; 3: 149-51.
4. Casteels I, De Loof E, Brock P, Jorissen M: Sudden blindness in a child: presenting symptom of a sphenoid sinus mucocele: *Brit J Ophthalmol* 1992; 76: 502-4.
5. Okuda T, Hanamure Y, Kasano F, Kashima N. Isolated sphenoid sinus lesions: a clinical analysis of 44 cases: *Nippon Jibiinkoka Gakkai Kaiho* 2005; 108: 835-41.
6. Heylbroeck P, Watelet JB, Delbeke P, Van Cauwenberge P, Bachert C. Vision impairment as presenting symptom of a sphenoidal mucocele; *Rhinology* 2003; 41: 187-91.
7. Vaphiades MS, Roberson GH. Sphenoid sinus mucocele presenting as a third cranial nerve palsy. *J Neuroophthalmol* 2005; 25: 293-4.
8. Wurster CE, Levine TM, Sisson GA. Mucocele of the sphenoid sinus causing sudden onset of blindness. *Otolaryngol Head Neck Surg* 1986; 94: 257-9.
9. Di Girolamo S, Cannizzaro P, Picciotti P, Nardi C. Ophthalmoplegia and ptosis as onset symptoms of an isolated primary mucocele of the sphenoid sinus. *J Oral Maxillofac Surg* 2002; 60: 1500-2.
10. Som PM. CT of the paranasal sinuses. *Neuroradiology* 1985; 27: 189-201.
11. Moriyama H, Hesaka H, Tachibana T, Honda Y. Mucocoeles of ethmoid and sphenoid sinus with visual disturbance. *Arch Otolaryngol Head Neck Surg* 1992; 118: 142-6.
12. Nerurkar NK, Bradoo R, Muranjan S, Khare M. Sphenoid sinus mucocele with unilateral blindness. *Ann Otol Rhinol Laryngol* 2004; 113: 294-6.